

**Sample History and Physical Note – (List Format)**  
**Charting Plus™ - Electronic Medical Records**  
[www.foxmeadows.com](http://www.foxmeadows.com)

Note for Jane Doe on 4/8/03 - Chart 1001001

**Chief Complaint (1/1):** This 59 year old female presents today complaining that her toenails are discolored, thickened, and painful.

**Duration:** Condition has existed for 6 months.

**Severity:** Severity of condition is worsening.

**Allergies:** Patient admits allergies to dairy products, penicillin.

**Medication History:** None.

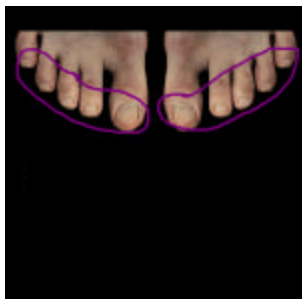
**Past Medical History:** Past medical history is unremarkable.

**Past Surgical History:** Patient admits past surgical history of eye surgery in 1999.

**Social History:** Patient denies alcohol use, Patient denies illegal drug use, Patient denies STD history, Patient denies tobacco use.

**Family History:** Unremarkable.

**Review of Systems: Psychiatric:** (+) poor sleep pattern, **Respiratory:** (+) breathing difficulties, respiratory symptoms.



**Physical Exam:** Patient is a 59 year old female who appears well developed, well nourished and with good attention to hygiene and body habitus. Toenails 1-5 bilateral appear crumbly, discolored - yellow, friable and thickened.

**Cardiovascular:** DP pulses palpable bilateral. PT pulses palpable bilateral. CFT immediate. No edema observed. Varicosities are not observed.

**Skin:** Skin temperature of the lower extremities is warm to cool, proximal to distal. No skin rash, subcutaneous nodules, lesions or ulcers observed.

**Neurological:** Touch, pin, vibratory and proprioception sensations are normal. Deep tendon reflexes normal.

**Musculoskeletal:** Muscle strength is 5/5 for all groups tested. Muscle tone is normal. Inspection and palpation of bones, joints and muscles is unremarkable.

**Test Results:** No tests to report at this time.

**Impression:** Onychomycosis.

**Plan:** Debrided 10 nails.

**Prescriptions:**

Penlac Dosage: 8% Topical Solution Sig: Dispense: Refills: 0 Allow Generic: No

\_\_\_\_\_  
Dr. Podiatry, DPM

**Sample History and Physical Note**  
**Charting Plus™ - Electronic Medical Records**  
[www.foxmeadows.com](http://www.foxmeadows.com)

**Chief Complaint (1/1):** This 24 year-old female presents today complaining of itchy, red rash on feet.

**Associated signs and symptoms:** Associated signs and symptoms include tingling right.

**Context:** Patient denies any previous history, related trauma or previous treatments for this condition.

**Duration:** Condition has existed for 4 weeks.

**Location:** She indicates the problem location is right great toe, right 2nd toe, right 3rd toe and right 4th toe.

**Modifying factors:** Patient indicates ice improves condition.

**Quality:** Quality of the itch is described by the patient as constant.

**Severity:** Severity of condition is unbearable.

**Timing (onset/frequency):** Onset was after leaving on sweaty socks.

**Allergies:** Patient admits allergies to adhesive tape resulting in severe rash.

**Medication History:** None.

**Past Medical History: Childhood Illnesses:** (+) chickenpox, (+) frequent ear infections.

**Past Surgical History:** Patient admits past surgical history of ear tubes.

**Social History:** Patient admits alcohol use Drinking is described as social, Patient denies tobacco use, Patient denies illegal drug use, Patient denies STD history.

**Family History:** Patient admits a family history of cataract associated with maternal grandmother, headaches/migraines associated with maternal aunt.

**Review of Systems:** Unremarkable with exception of chief complaint.

**Physical Exam:** BP Sitting: 110/64 Resp: 18 HR: 66 Temp: 98.6

Patient is a 24 year old female who appears well developed, well nourished and with good attention to hygiene and body habitus.

**Cardiovascular:** Skin temperature of the lower extremities is warm to cool, proximal to distal.

DP pulses palpable bilateral.

PT pulses palpable bilateral.

CFT immediate.

No edema observed.

Varicosities are not observed.

**Skin:** Right great toe, right 2nd toe, right 3rd toe and right 4th toenail shows erythema and scaling.

**Neurological:** Touch, pin, vibratory and proprioception sensations are normal.

Deep tendon reflexes normal.

**Musculoskeletal:**

Muscle strength is 5/5 for all groups tested.

Muscle tone is normal.

Inspection and palpation of bones, joints and muscles is unremarkable.

**Test Results:** No tests to report at this time

**Impression:** Tinea pedis.

**Plan:**

Obtained fungal culture of skin from right toes.

KOH prep performed revealed no visible microbes.

**Prescriptions:**

Lotrimin AF Dosage: 1% cream Sig: apply qid Dispense: 4oz tube Refills: 0 Allow Generic: Yes

\_\_\_\_\_  
Dr. Podiatry, DPM

**Sample Referral Letter**  
**Charting Plus™ - Electronic Medical Records**  
[www.foxmeadows.com](http://www.foxmeadows.com)

4/8/03

A. General Practitioner, MD  
1231 8<sup>th</sup> Street, Suite 222  
West Des Moines, IA 50265

Dear Dr. General Practitioner:

Jane Doe was seen in my office in consultation as requested by you as a new patient for evaluation and care. The following is a summary of my findings and recommendations:

**Impression:** Tinea pedis.

**Plan:**

Obtained fungal culture of skin from right toes.  
KOH prep performed revealed no visible microbes.

**Prescriptions:**

Lotrimin AF Dosage: 1% cream Sig: apply qid Dispense: 4oz tube Refills: 0 Allow Generic: Yes

If I may be of any further assistance in the care of your patient, please let me know. Thank you for providing me the opportunity to participate in the care of your patients.

Sincerely,

Dr. Podiatry, DPM

# Sample Patient Instruction

## Charting Plus™ - Electronic Medical Records

[www.foxmeadows.com](http://www.foxmeadows.com)

Patient Instructions for Jane Doe on 4/8/03

### ATHLETE'S FOOT

What is it?

Athlete's foot, tinea pedis, is a very common fungal skin infection of the foot. It often first appears between the toes. It can be a one-time occurrence or it can be chronic. The fungus, known as Trichophyton, thrives under warm, damp conditions so people whose feet sweat a great deal are more susceptible. It is easily transmitted in showers and pool walkways. Those people with immunosuppressive conditions, such as diabetes mellitus, are also more susceptible to athlete's foot.

Signs and symptoms:

- \* Itchy feet.
- \* White or red and soft scaling on feet, usually in between toes.
- \* Small blisters may be present.
- \* Bad foot odor.
- \* Very rare involvement of hands and simultaneously (called an Id reaction).

Treatment:

- \* Diagnosis is via symptoms or sometimes by examining skin scrapings under a microscope.. A bacterial infection may also be suspected in which case a skin culture will confirm this.
- \* Try a non-prescription antifungal powder or cream available in drugstores; your doctor can prescribe a stronger topical antifungal medication if necessary.
- \* Oral antibiotics may be prescribed for a possible bacterial infection.
- \* Keep feet as dry as possible! Change socks twice a day if necessary and wear those made of natural fibers, such as cotton. Go barefoot when you have a chance or wear sandals. Dry thoroughly in between toes after swimming or bathing.
- \* A special powder to absorb moisture on feet is also available in drugstores. Ask the pharmacist about this.
- \* Spray your shower at home with a 10% bleach solution after bathing. This may help decrease the chance that other family members will be infected.
- \* Wear sandals or thongs in public showers and around pools.
- \* Keep in mind that it may take up to a month or more to get rid of your athlete's foot. Be diligent in using the antifungal medication. Unfortunately, recurrence of athlete's foot is common. Luckily, the condition does not cause serious problems for the majority of people who have it.
- \* Call the office if your athlete's foot spreads or worsens despite treatment.

### PLANTAR FASCIAL STRETCHES

1. Raise toes toward you while bending your ankle as high as you can.
2. Hold this position for 15 seconds.
3. Alternate doing this with the opposite foot 10 times.
4. Perform this exercise 2- 3 times a day.

### WOUND CARE INSTRUCTIONS

1. Clean the area daily with soap and water.
2. Every day apply a thin coat of polysporin ointment.
3. Change the dressing daily and keep the area covered with an adhesive bandage until completely healed.
4. Notify the office if you have any increasing wound pain or any evidence of infection.

---

Dr. Podiatry, DPM

**Sample Billing Statement**  
**Charting Plus™ - Electronic Medical Records**  
[www.foxmeadows.com](http://www.foxmeadows.com)

**Billing Statement - Monday, September 16, 2002**

**Provider:** A. Podiatrist  
**Patient:** Jane Doe, Chart 1001001  
1231 8<sup>th</sup> Street, Suite 200  
West Des Moines, IA 50266

**Diagnoses**

1. 110.4 Dermatophytosis Of Foot

**Treatments**

1. 87101 Culture, Fungi (Mold Or Yeast) Isolation, With Presumptive Identification Of Isolates; Skin, Hair, Or Nail  
Related Diagnoses:  
Modifiers:  
Units:
2. 87220 Tissue Examination By KOH Slide Of Samples From Skin, Hair, Or Nails For Fungi Or Ectoparasite Ova Or Mites (eg, Scabies)  
Related Diagnoses:  
Modifiers:  
Units:
3. 99201 Office or other outpatient visit - new patient - 10 min.  
Related Diagnoses:  
Modifiers:  
Units:

**Referring Physician:** A. General Practitioner  
**Date Last Seen:** 09/16/2002

**Sample Prescription**  
**Charting Plus™ - Electronic Medical Records**  
[www.foxmeadows.com](http://www.foxmeadows.com)

Dr. Podiatry, DPM

DEA#:

---

Name: Jane Doe  
Addr: 1231 8th Street, Suite 222  
West Des Moines, IA 50265

---

Date: 4/8/03

Lotrimn AF  
1% cream  
qid

X \_\_\_\_\_ X \_\_\_\_\_  
Substitution Permitted Dispense as written

Refills: 0  
Disp: 4oz tube  
Allow Generic: Yes

**Sample Operative Report – Keller Bunionectomy**  
**Charting Plus™ - Electronic Medical Records**  
[www.foxmeadows.com](http://www.foxmeadows.com)

Note for Jane Doe on 4/8/03 - Chart 1001001

**OPERATIVE REPORT**

**Surgeon:** Dr. Podiatry, DPM

**Assistants:** None

**Post-op Diagnosis:** No change in assessment this date.

**Procedure:** Keller Bunionectomy

For informed consent, the more common risks, benefits, and alternatives to the procedure were thoroughly discussed with Jane. An appropriate consent form was signed, indicating Jane understands the procedure and its possible complications.

This 59 year-old female was brought to the operating room and placed on the surgical table in a supine position. Following anesthesia, the surgical site was prepped and draped in the normal sterile fashion. Attention was then directed to the right foot where, utilizing a # 15 blade, a 6 cm. linear incision was made over the 1st metatarsal head, taking care to identify and retract all vital structures. The incision was medial to and parallel to the extensor hallucis longus tendon. The incision was deepened through subcutaneous underscoring, retracted medially and laterally — thus exposing the capsular structures below, which were incised in a linear longitudinal manner, approximately the length of the skin incision. The capsular structures were sharply underscoring off the underlying osseous attachments, retracted medially and laterally.

Utilizing an osteotome and mallet, the exostosis was removed, and the head was remodeled with the Liston bone forceps and the bell rasp. The surgical site was then flushed with saline. The base of the proximal phalanx of the great toe was osteotomized approximately 1 cm. distal to the base and excised to toto from the surgical site. Superficial closure was accomplished using Vicryl 5-0 in a running subcuticular fashion. Site was dressed with a light compressive dressing. The tourniquet was released. Excellent capillary refill to all the digits was observed without excessive bleeding noted.

**Anesthesia:** local.

**Hemostasis:** Accomplished with pinpoint electrocoagulation.

**Estimated Blood Loss:** 10 cc.

**Materials:** None.

**Injectables:** Agent used for local anesthesia was Lidocaine 2% without epi.

**Pathology:** Sent no specimen.

**Dressings:** Site was dressed with a light compressive dressing.

**Condition:** Patient tolerated procedure and anesthesia well. Vital signs stable. Vascular status intact to all digits. Patient recovered in the operating room.

**Scheduling:** Return to clinic in 2 week(s).

---

Dr. Podiatry, DPM