

Note for John Doe on 7/22/2005 - Chart 1583

Chief Complaint (1/1): This 50-year-old male presents today with shoulder pain right.

(Ortho) Location: He indicates the problem location is the anterior right shoulder in general. The pain tends to radiate distally.

(Ortho) Description/Impairment: the patient describes the pain as having a throbbing quality, being a radiating type of pain and preventing R.O.M. in the joint.

(Ortho) Current Status: Rest and Analgesics have helped the pain very little.

(Ortho) Symptoms Increased By: He states the symptoms are made worse with attempted use of the injured area.

(Ortho) Duration: Condition has been present for about 5 days. John has missed work for the past 5 days.

Allergies: Patient admits allergies to codeine resulting in mild rash.

Medication History: Patient is currently using ibuprofen film-coated tablets 600 mg tablet, coated (as needed).

Past Medical History: **Endocrine Hx:** (+) diabetes, controlled by oral hypoglycemics, **Respiratory Hx:** (+) asthma, bronchial.

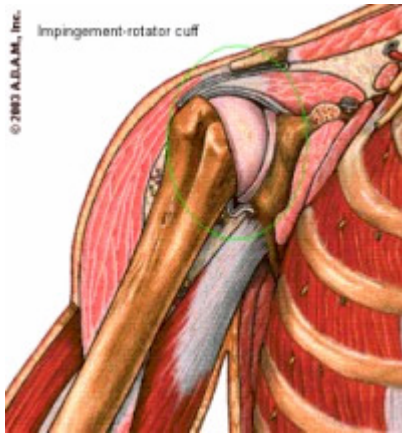
Past Surgical History: Patient admits past surgical history of appendectomy in 1977.

Family History: Patient admits a family history of cancer of prostate associated with father (deceased).

Social History: Patient admits alcohol use. Drinking is described as social, Patient admits caffeine use. He consumes 3-5 servings per day, Patient denies STD history, Patient denies illegal drug use, and Patient denies tobacco use.

Review of Systems: Musculoskeletal: (+) difficulty/limited exercise, (+) joint or musculoskeletal symptoms,

Gastrointestinal: (+) unremarkable, **Ears, Nose, Mouth, Throat:** (+) unremarkable, **Constitutional Symptoms:** (+) unremarkable, **Allergic / Immunologic:** (+) eyes watering, **Cardiovascular:** (-) chest pain.



Physical Exam: BP Sitting: 120/80 Resp: 20 HR: 72 Temp: 98.6 Height: 5 ft. 10 in. Weight: 187 lbs. BMI: 27

Patient is a 50 year old male who appears pleasant, in no apparent distress, his given age, well developed, well nourished and with good attention to hygiene and body habitus. Oriented to person, place and time. Mood and affect normal, appropriate to situation. Right shoulder shows evidence of tenderness. Deep tendon reflexes normal. Touch, pin, vibratory and proprioception sensations are normal. Two-point discrimination is within normal limits.

Appearance: Normal.

Tenderness: (+) Tenderness: anterior capsule - moderate, biceps tendon/ bicipital groove - none and posterior capsule - moderate right.

Range of Motion: Range of motion: Right Shoulder ROM shows decreased flexion, decreased extension, decreased adduction, decreased abduction, decreased internal rotation, decreased external rotation. L shoulder normal.

Strength: Rotator cuff strength testing: supraspinatus: 4+/5, internal rotators: 4/5 and is associated with pain. No scapula hiking (asymmetry) with shoulder abduction.

AC Joint: Normal.

Rotator Cuff: (+) Impingement test: - moderate right.
Instability: None.

Test & X-Ray Results: X-ray's right shoulder (2 views) today 7/22/2005 Impression: cuff arthropathy present.

Impression: Rotator cuff syndrome right.

Plan: Diagnosis of a rotator cuff tendonitis and shoulder impingement was discussed. I noted that this is a very common condition resulting in significant difficulties with use of the arm.

Several treatment options and their potential benefits were described. Nonsteroidal anti-inflammatories can be helpful but typically are slow acting.

Cortisone shots can be very effective and are quite safe. Often more than one injection may be required. Physical therapy can also be helpful, particularly if there is any loss of shoulder mobility or strength.

If these treatments fail to resolve symptoms, an MRI or shoulder arthrogram may be required to rule out a rotator cuff tear. Corticosteroid used for injection was Celestone 3 mg. Location: right shoulder. Manufacturer: Johnson. Expiration date: 7/22/2005. Lot number: 1234. Physical therapist was given orders to evaluate patient's condition and treat accordingly. **Scheduling:** Return to clinic in 1 week(s).

Prescriptions:

Arthrotec 50 Dosage: 50 mg-200 mcg tablet Sig: One PO BID Dispense: 60 Refills: 3 Allow Generic: Yes

Patient Instructions:

Patient instructed to consult pharmacist for NSAIDs.
Patient was given instructions on RICE therapy.

Digitally Signed on 7/22/2005 By: A. Orthopedist, M.D.

7/22/05

A. General Practitioner,
1025 Ashworth Road, Suite 222
West Des Moines, IA 50265

Dear Dr. General:

John Doe was seen in my office in consultation as requested by you as a new patient for evaluation and care. The following is a summary of my findings and recommendations:

Impression: cuff arthropathy present.

Impression: Rotator cuff syndrome right.

Plan: Diagnosis of a rotator cuff tendonitis and shoulder impingement were discussed. I noted that this is a very common condition resulting in significant difficulties with use of the arm.

Several treatment options and their potential benefits were described. Nonsteroidal anti-inflammatories can be helpful but typically are slow acting.

Cortisone shots can be very effective and are quite safe. Often more than one injection may be required. Physical therapy can also be helpful, particularly if there is any loss of shoulder mobility or strength.

If these treatments fail to resolve symptoms, an MRI or shoulder arthrogram may be required to rule out a rotator cuff tear. Corticosteroid used for injection was Celestone 3 mg. Location: right shoulder. Manufacturer: Johnson. Expiration date: 01/24/2005. Lot number: 1234. Physical therapist was given orders to evaluate patient's condition and treat accordingly. **Scheduling:** Return to clinic in 1 week(s).

Prescriptions:

Arthrotec 50 Dosage: 50 mg-200 mcg tablet Sig: One PO BID Dispense: 60 Refills: 3 Allow Generic: Yes

Patient Instructions:

Patient instructed to consult pharmacist for NSAIDs.

Patient was given instructions on RICE therapy.

If I may be of any further assistance in the care of your patient, please let me know. Thank you for providing me the opportunity to participate in the care of your patients.

Sincerely,

A. Orthopedist, MD

Patient Instructions for John Doe on 7/22/05

NSAIDs:

Consult your pharmacist regarding over-the-counter nonsteroidal anti-inflammatory medications.

RICE THERAPY

RICE stands for the most important elements of treatment for many injuries---rest, ice, compression, and elevation.

Rest:

Stop using the injured part as soon as you realize that an injury has taken place. Use crutches to avoid bearing weight on injuries of the foot, ankle, knee, or leg. Use splints for injuries of the hand, wrist, elbow, or arm. Continued exercise or activity could cause further injury, increased pain, or a delay in healing.

Ice:

Ice helps stop bleeding from injured blood vessels and capillaries. Sudden cold causes the small blood vessels to contract. This contraction decreases the amount of blood that can collect around the wound. The more blood that collects, the longer the healing time. Ice can be safely applied in many ways:

* For injuries to small areas, such as a finger, toe, foot, or wrist, immerse the injured area for 15 to 35 minutes in a bucket of ice water. Use ice cubes to keep the water cold, adding more as the ice cubes dissolve.

* For injuries to larger areas, use ice packs. Avoid placing the ice directly on the skin. Before applying the ice, place a towel, cloth, or one or two layers of an elasticized compression bandage on the skin to be iced. To make the ice pack, put ice chips or ice cubes in a plastic bag or wrap them in a thin towel. Place the ice pack over the cloth. The pack may sit directly on the injured part, or it may be wrapped in place.

* Ice the injured area for about 30 minutes.

* Remove the ice to allow the skin to warm for 15 minutes.

* Reapply the ice.

* Repeat the icing and warming cycles for 3 hours. Follow the instructions below for compression and elevation. If pain and swelling persist after 3 hours call our office. You may need to change the icing schedule after the first 3 hours. Regular ice treatment is often discontinued after 24 to 48 hours. At that point, heat is sometimes more comfortable.

Compression:

Compression decreases swelling by slowing bleeding and limiting the accumulation of blood and plasma near the injured site. Without compression, fluid from adjacent normal tissue seeps into the injured area.

To apply compression safely to an injury:

* Use an elasticized bandage (Ace bandage) for compression, if possible. If you do not have one available, any kind of cloth will suffice for a short time.

* Wrap the injured part firmly, wrapping over the ice. Begin wrapping below the injury site and extend above the injury site.

* Be careful not to compress the area so tightly that the blood supply is impaired. Signs of deprivation of the blood supply include pain, numbness, cramping, and blue or dusky nails. Remove the compression bandage immediately if any of these symptoms appears. Leave the bandage off until all signs of impaired circulation disappear. Then rewrap the area--less tightly this time.

Elevation:

Elevating the injured part above the level of the heart is another way to decrease swelling and pain at the injury site. Elevate the iced, compressed area in whatever way is most convenient. Prop an injured leg on a solid object or pillows. Elevate an injured arm by lying down and placing pillows under the arm or on the chest with the arm folded across.

A. Orthopedist, MD

Orthopaedic Clinic

1025 Ashworth Road, Suite 222
West Des Moines IA 50265

PRESCRIBER: A. Orthopedist, MD

TELEPHONE: (515)327-8850

DEA: 123456789

PATIENT: John Doe
ADDRESS: 123 Main Street
West Des Moines, IA 50265

TELEPHONE: 515-327-8850
DOB: 11-30-1954
DATE: 7/22/2005

R_x

Arthrotec 50 50 mg-200 mcg tablet

Disp: 60

Sig: One PO BID

Refills: 3

DISPENSE AS WRITTEN
 GENERIC SUBSTITUTION PERMITTED

SIGNATURE OF PRESCRIBER

Billing Statement - Friday, July 22, 2005

Provider: A. Orthopedist, MD
Patient: John Doe, Chart 1583
1025 Ashworth Road, Suite 222
West Des Moines, IA 50265

Diagnoses

1. 726.10 Disorders Of Bursae And Tendons In Shoulder Region, Unspecified

Treatments

1. 20610 Arthrocentesis, Aspiration And/Or Injection; Major Joint Or Bursa (eg, Shoulder, Hip, Knee Joint, Subacromial Bursa)
Related Diagnoses: 726.10
Modifiers:
Units:
2. 99202 Office or other outpatient visit - new patient - 20 min.
Related Diagnoses: 726.10
Modifiers:
Units:
3. 73020 Radiologic Examination, Shoulder; One View
Related Diagnoses: 726.10
Modifiers:
Units:

Referring Physician: A. General Practitioner, MD
Date Last Seen: 06/12/2004